Chapter 13. Vesicoureteral Reflux

Emil A. Tanagho, MD; Hiep T. Nguyen, MD

Vesicoureteral Reflux: Introduction

Under normal circumstances, the ureterovesical junction allows urine to enter the bladder but prevents urine from regurgitating into the ureter, particularly at the time of voiding. In this way, the kidney is protected from high pressure in the bladder and from contamination by infected vesical urine. When this valve is incompetent, the chance for development of urinary infection is significantly enhanced, and pyelonephritis may occur. In significant cases especially in children, pyelonephritis—acute, chronic, or healed—is secondary to vesicoureteral reflux (VUR).

Anatomy of the Ureterovesical Junction

An understanding of the causes of VUR requires knowledge of the anatomy of the ureterovesical valve. Anatomic studies performed by Hutch (1972) and by Tanagho and Pugh (1963) (Figure 13–1) are incorporated into the following discussion.

Figure 13–1.

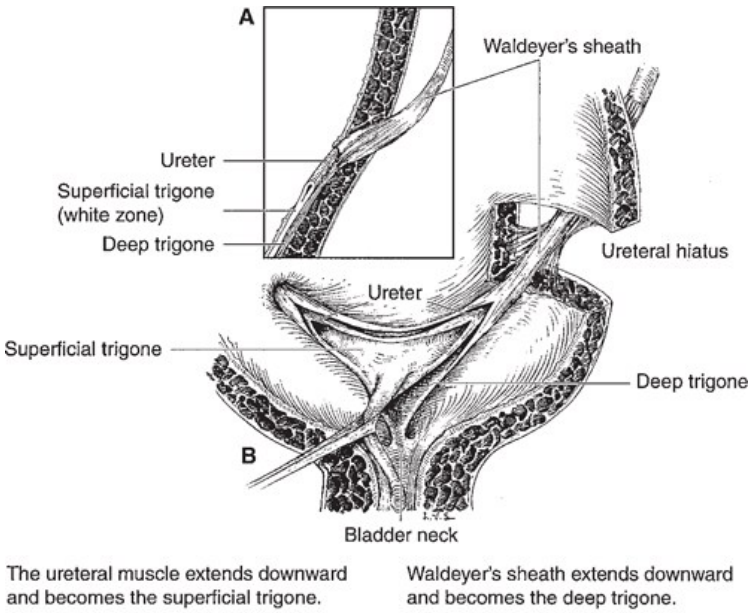

Source: McAninch JW, Lue TF: *Smith & Tanagho's General Urology*, 18th Edition: www.accessmedicine.com

Normal ureterotrigonal complex. ***A:*** Side view of ureterovesical junction. Waldeyer's muscular sheath invests the juxtavesical ureter and continues downward as the deep trigone, which extends to the bladder neck. The ureteral musculature becomes the superficial trigone, which extends to the verumontanum in the male and stops just short of the external meatus in the female. ***B:*** Waldeyer's sheath is connected by a few fibers to the detrusor muscle in the ureteral hiatus. This muscular sheath, inferior to the ureteral orifices, becomes the deep trigone. The musculature of the ureters continues downward as the superficial trigone. (Redrawn and modified, with permission, from Tanagho EA, Pugh RCB: The anatomy and function of the ureterovesical junction. Br J Urol 1963;35:151.)

Mesodermal Components

The mesodermal component, which arises from the Wolffian duct, is made up of two parts that are innervated by the sympathetic nervous system:

The Ureter and the Superficial Trigone

The smooth musculature of the renal calyces, pelvis, and extravesical ureter is composed of helically oriented fibers that allow for peristaltic activity. As these fibers approach the vesical wall, they are reoriented into the longitudinal plane. The ureter passes obliquely through the vesical wall; the intravesical ureteral segment is thus composed of longitudinal muscle fibers only and therefore cannot undergo peristalsis. As these smooth-muscle fibers approach the ureteral orifice, those that form the roof of the ureter swing to either side to join those that form its floor. They then spread out and join equivalent muscle bundles from the other ureter and also continue caudally, thus forming the superficial trigone. The trigone passes over the neck of the bladder, ending at the verumontanum in the male and just inside the external urethral meatus in the female. Thus, the ureterotrigonal complex is one structure. Above the ureteral orifice, it is tubular; below that point, it is flat.

Waldeyer's Sheath and the Deep Trigone

Beginning at a point about 2–3 cm above the bladder, an external layer of longitudinal smooth muscle surrounds the ureter. This muscular sheath passes through the vesical wall, to which it is connected by a few detrusor fibers. As it enters the vesical lumen, its roof fibers diverge to join its floor fibers, which then spread out, joining muscle bundles from the contralateral ureter and forming the deep trigone, which ends at the bladder neck.

Endodermal Component

The vesical detrusor muscle bundles are intertwined and run in various directions. As they converge on the internal orifice of the bladder, however, they tend to become oriented into three layers.

Internal Longitudinal Layer

The internal longitudinal layer continues into the urethra submucosally and ends just inside the external meatus in the female and at the caudal end of the prostate in the male.

Middle Circular Layer

The middle circular layer is thickest anteriorly and stops at the vesical neck.

Outer Longitudinal Layer

The muscle bundles of the outer longitudinal layer take a circular and spiral course about the external surface of the female urethra and are incorporated within the peripheral prostatic tissue in the male. They constitute the true vesicourethral sphincter.

The vesical detrusor muscle is innervated by the parasympathetic nerves (S_2–S_4).

Physiology of the Ureterovesical Junction

Although many investigators had suspected that normal trigonal tone tended to occlude the intravesical ureter, it remained for Tanagho et al (1965) to prove it. Using nonrefluxing dogs, they demonstrated the following:

1. Interruption of the continuity of the trigone resulted in reflux. An incision was made in the trigone 3 mm below the ureteral orifice, resulting in an upward and lateral migration of the ureteral orifice with shortening of the intravesical ureter. Reflux was demonstrable. After the incision healed, reflux ceased.

2. Unilateral lumbar sympathectomy resulted in paralysis of the ipsilateral trigone. This led to lateral and superior migration of the ureteral orifice and reflux.

3. Electrical stimulation of the trigone caused the ureteral orifice to move caudally, thus lengthening the intravesical ureter. This maneuver caused a marked rise in resistance to flow through the ureterovesical junction. Ureteral efflux of urine ceased. Intravenous injection of epinephrine caused the same reaction. On the other hand, isoproterenol caused the degree of occlusion to drop below normal. If the trigone was incised, however, electrical stimulation of the trigone or the administration of epinephrine failed to increase ureteral occlusive pressure.

4. During gradual filling of the bladder, intravesical pressure increased only slightly, whereas pressure within the intravesical ureter rose progressively—owing, apparently, to increasing trigonal stretch. A few seconds before the expected sharp rise in intravesical pressure generated for voiding, the closure pressure in the intravesical ureter rose sharply and was maintained for 20 seconds after detrusor contraction had ceased. This experiment demonstrated that ureterovesical competence is independent of detrusor action and is governed by the tone of the trigone, which contracts vigorously just before voiding, thus helping to open and funnel the vesical neck. At the same time, significant pull is placed on the intravesical ureter so that it is occluded during the period when intravesical pressure is high. During the voiding phase, there is naturally no efflux of ureteral urine.

One may liken this function to the phenomenon of the Chinese thimble: The harder the finger (trigone) pulls, the tighter the thimble (intravesical ureter) becomes. Conversely, a deficient pull may lead to incomplete closure of the ureterovesical junction.

It was concluded from these experiments that normal ureterotrigonal tone prevents VUR. Electrical or pharmacologic stimulation of the trigone caused increased occlusive pressure in the intravesical ureter and increased resistance to flow down the ureter, whereas incision or paralysis of the trigone led to reflux. The theory that ureterovesical competence was maintained by intravesical pressure compressing the intravesical ureter against its backing of detrusor muscle was thereby disproved.

Biopsy of the trigone (and the intravesical ureter) in patients with primary reflux revealed marked deficiency in the development of its smooth muscle (Figure 13–2). Electrical stimulation of such a trigone caused only a minor contraction of the ureterotrigonal complex. This work led to the conclusion that the common cause of reflux, particularly in children, is congenital attenuation of the ureterotrigonal musculature.

Figure 13–2.

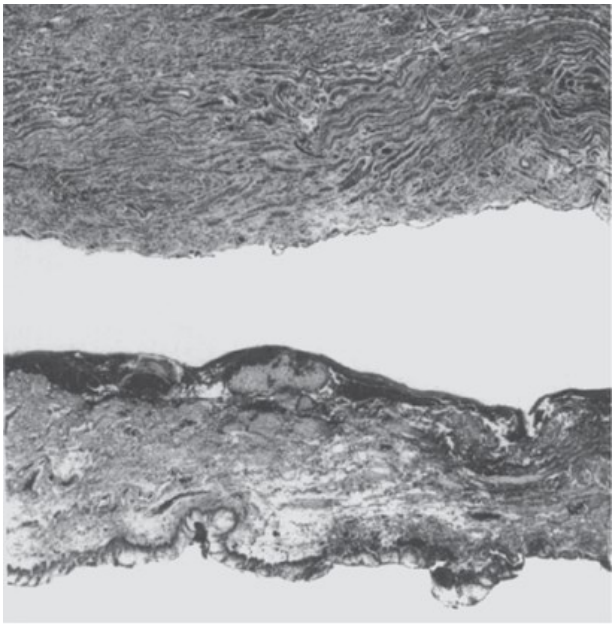

Source: McAninch JW, Lue TF: *Smith & Tanagho's General Urology*, 18th Edition: www.accessmedicine.com

Histology of the trigone in primary reflux. ***Top:*** Normal trigone demonstrating wealth of closely packed smooth-muscle fibers. ***Bottom:*** The congenitally attenuated trigonal muscle that accompanies vesicoureteral reflux. Note the absence of inflammatory cell. (Reproduced, with permission, from Tanagho EA et al: Primary vesicoureteral reflux: Experimental studies of its etiology. J Urol 1965;93:165.)

Vesicoureteral Reflux

Causes

The major cause of VUR is attenuation of the trigone and its contiguous intravesical ureteral musculature. Any condition that shortens the intravesical ureter may also lead to reflux, but this is less common. Familial VUR has been observed by a number of authors. It appears to be a genetic trait.

Congenital Causes

Trigonal Weakness (Primary Reflux)

Trigonal weakness is by far the most common cause of ureteral reflux. It is most often seen in young children, more common in girls than in boys. Reflux in adults—usually women—probably represents the same congenital defect. Weakness of one side of the trigone leads to a decrease in the occlusive pressure in the ipsilateral intravesical ureter. Diffuse ureterotrigonal weakness causes bilateral reflux.

It is postulated that ureteral trigonal weakness is related to the development of the ureteral bud on the mesonephric duct. It is known that the ureter acquires its musculature from its cranial end caudally so that if a segment is muscularly deficient, it is deficient in its most caudal part. It is also postulated that if the ureter is too close to the urogenital sinus on the mesonephric duct, it will join the latter relatively early in embryonic life, before acquiring adequate mesenchymal tissue around itself to be differentiated later into proper trigonal musculature as well as lower ureter. This embryologic hypothesis explains all the known features of refluxing ureters: their muscular weakness, their lateral placement on the bladder base with a very short submucosal segment, and their usual association with weak ureteral musculature and gaping ureteral orifices (which, in severe cases, ensures a golf-hole endoscopic appearance at their junction with the bladder wall). It also explains why, in duplicated systems, if there is only one refluxing unit, it is the upper orifice (which originated closer to the urogenital sinus on the mesonephric duct and thus has the least muscular development).

In the normal state, the intravesical ureterotrigonal muscle tone exerts a downward pull, whereas the extravesical ureter tends to pull cephalad (Figure 13–3). If trigonal development is deficient, not only is its occlusive power diminished but the ureteral orifice tends to migrate upward toward the ureteral hiatus. The degree of this retraction relates to the degree of incompetence of the junction (Figure 13–4). If the ureteral orifice lies over the ureteral hiatus in the bladder wall (so-called golf-hole orifice), it is completely incompetent. The degree of incompetence is judged by the findings on excretory urography and cystography and the cystoscopic appearance of the ureteral orifices.

Figure 13–3.

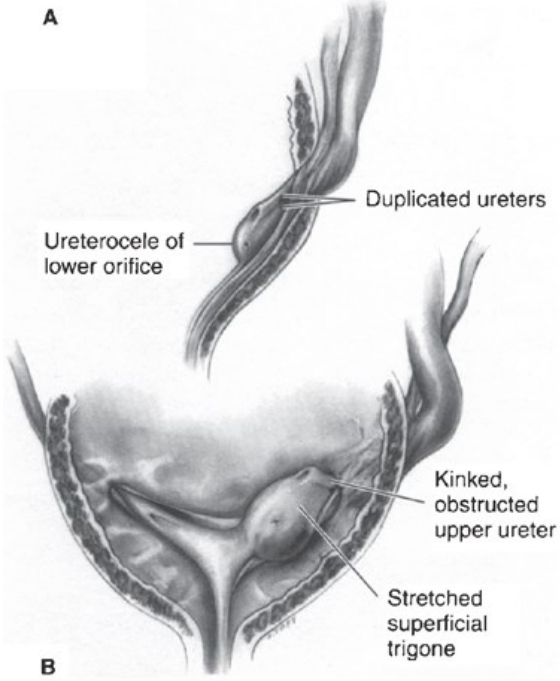

Source: McAninch JW, Lue TF: *Smith & Tanagho's General Urology*, 18th Edition: www.accessmedicine.com

A: Small ureterocele developing in a duplicated system (where it always involves a lower ureteral orifice). ***B:*** Expansion of submucosal segment leads to lifting and angulation of ipsilateral lower pole ureteral orifice. Duplicated system ureteroceles are rarely so small. (Diagrammatic representation.) (Reproduced, with permission, from Tanagho EA: Ureteroceles: Embryogenesis, pathogenesis and management. J Cont Educ Urol 1979;18:13.)

Figure 13–4.

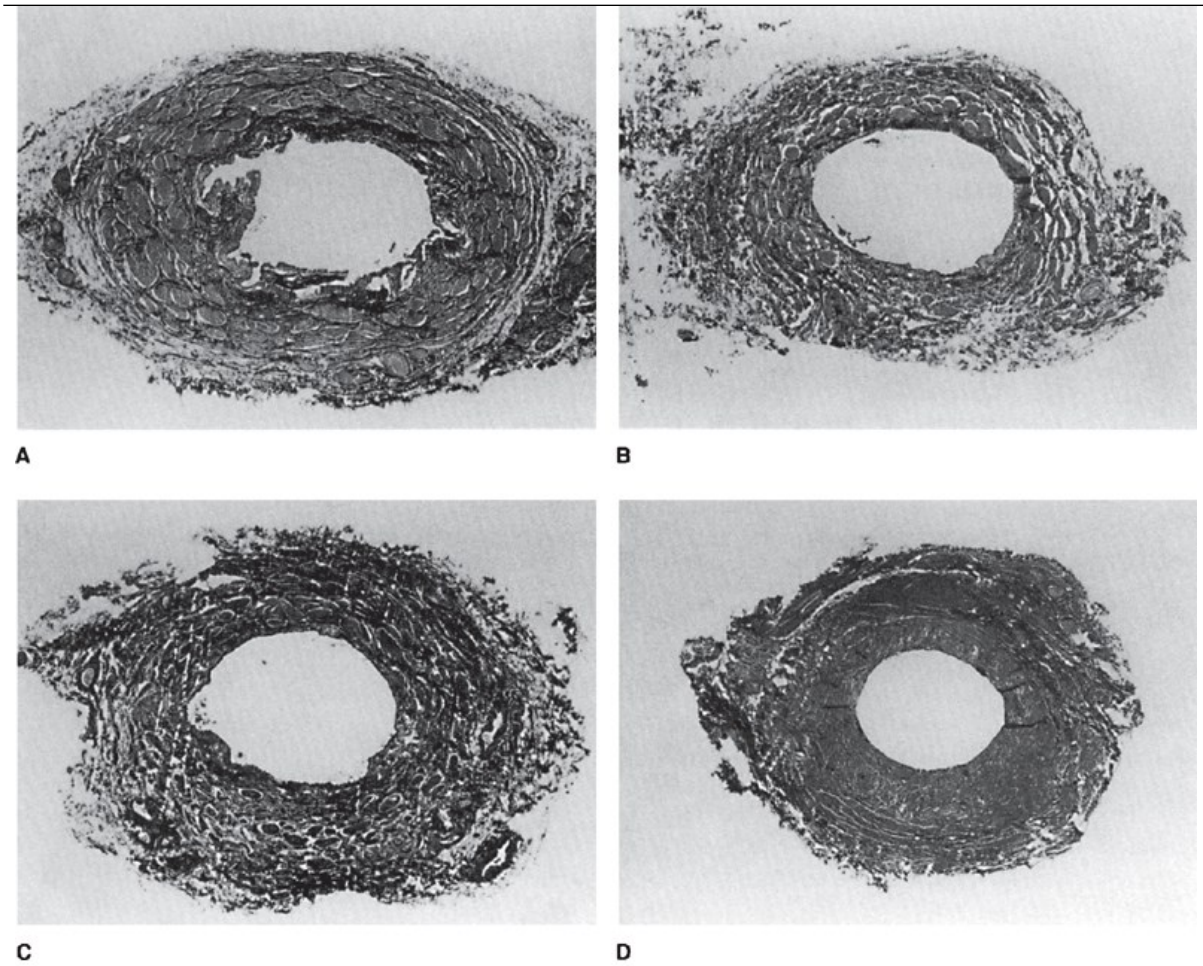

Source: McAninch JW, Lue TF: *Smith & Tanagho's General Urology*, 18th Edition: www.accessmedicine.com

Histology of the various grades of submucosal muscular weakness of the ureteral orifice. (See also Figure 13–9.) ***A:*** Normal. Minimal deficiency. (Cone orifice.) ***B:*** More marked muscular weakness. (Stadium orifice.) ***C:*** Marked muscular deficiency. (Horseshoe orifice.) ***D:*** Extreme muscular deficiency. Only a few muscle fibers can be seen; the rest is collagen tissue.

Familial Reflux

There appears to be genetic predisposition for reflux. The reported prevalence of VUR among siblings of index patients with reflux has ranged from 4.7% to 51%, which is significantly higher than the incidence of reflux in the general population (1%) (Ataei et al, 2004). In addition, the incidence of reflux varies among nationalities and races. Studies involving genotype screening of specific subgroups of patients suggest that there is heterogeneity in the genetics of VUR (reviewed by Carvas et al, 2010). Several genes have been associated with VUR, including uroplakin-3, SLIT2/ROBO2, and TGF-β. In addition, several chromosomal regions (on chromosomes 1, 2, 3, 5, 13, and 18) have also been identified. Despite extensive analysis, the exact form of genetic transmission has yet to be delineated.

Ureteral Abnormalities

Complete Ureteral Duplication (Figure 13–5)

The intravesical portion of the ureter to the upper renal segment is usually of normal length, whereas that of the ureter to the lower pole is abnormally short; this orifice is commonly incompetent. However, Stephens (1957) demonstrated that the musculature of the superiorly placed orifice is attenuated, which further contributes to its weakness.

Figure 13–5.

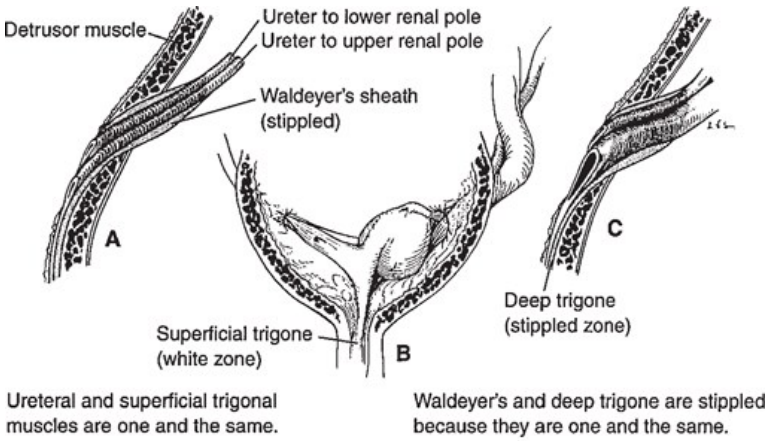

Source: McAninch JW, Lue TF: *Smith & Tanagho's General Urology*, 18th Edition: www.accessmedicine.com

Ureteral duplication and ureterocele as causes of vesicoureteral reflux. ***A:*** Ureteral duplication showing juxtavesical and intravesical ureters encased in common sheath (Waldeyer's). The superior ureter, which always drains the lower renal pole, has a shorter intravesical segment; in addition, it is somewhat devoid of muscle. It therefore tends to allow reflux. ***B:*** Duplication with ureterocele that always involves caudal ureter, which drains upper renal pole. Pinpoint orifice is obstructive, causing hydroureteronephrosis. Resulting wide dilatation of ureter and ureteral hiatus shortens the intravesical segment of the other ureter, often causing it to reflux. **C:** Resection of ureterocele allows reflux into that ureter.

Ectopic Ureteral Orifice

Single ureter or one of a pair may open well down on the trigone, at the vesical neck, or in the urethra. In this instance, VUR is the rule. This observation makes it clear that the length of the intravesical ureter is not the sole factor in reflux. Such intravesical ureteral segments are usually devoid of smooth muscle. Thus, they have no occlusive force.

Ureterocele

A ureterocele involving a single ureter rarely allows reflux, but this lesion usually involves the ureter that drains the upper pole of a duplicated kidney. Because the ureteral orifice is obstructed, the intramural ureter becomes dilated. This increases the diameter of the ureteral hiatus, further shortening the intravesical segment of the other ureter, which therefore may become incompetent. Resection of the ureterocele usually causes its ureter to reflux freely as well.

Voiding Dysfunction

Abnormal voiding habits have been associated with reflux. Toilet-trained children, in particular girls, may alter their bladder function by inhibiting their urge to void. This can result in abnormally high voiding pressure, bladder overactivity, and poor bladder compliance. These changes in bladder dynamics can either induce the development of primary reflux or prevent its resolution (Greenfield and Wan, 2000). In addition, alterations in the bowel function (eg, constipation) can cause further deterioration in bladder function and consequently the development or persistence of primary reflux (Bower et al, 2005).

Vesical Trabeculation

Occasionally, a heavily trabeculated bladder may be associated with reflux. The causes include spastic neurogenic bladder and severe obstruction distal to the bladder. These lesions, however, are associated with trigonal hypertrophy as well; the resultant extra pull on the ureterotrigonal muscle tends to protect the junction from incompetence. In a few such cases, however, the vesical mucosa may protrude through the ureteral hiatus just above the ureter to form a diverticulum, or saccule (Figure 13–6). The resulting dilatation of the hiatus shortens the intravesical segment; reflux may then occur.

Figure 13–6.

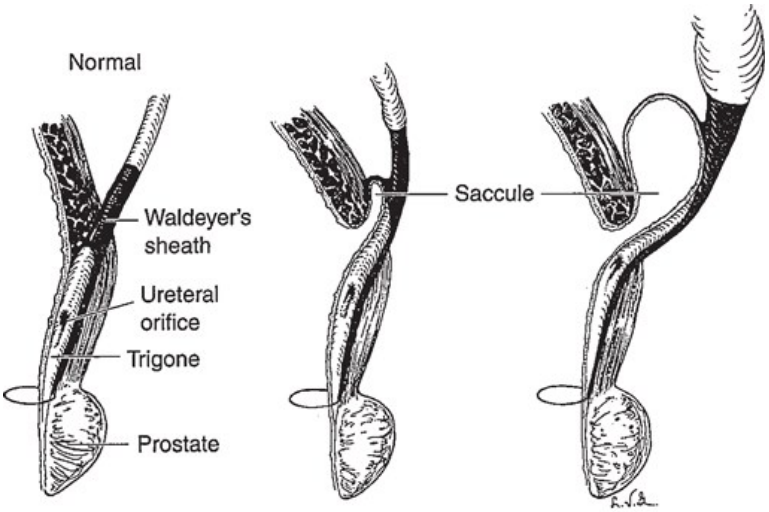

Source: McAninch JW, Lue TF: *Smith & Tanagho's General Urology*, 18th Edition: www.accessmedicine.com

Development of ureteral saccule, seen occasionally in cases of primary reflux but more commonly in obstructed or neurogenic bladders with marked trabeculation. Note that the vesical mucosa herniates through the ureteral hiatus, pulling the ureteral orifice upward with it. The orifice may ultimately open in the saccule rather than in the bladder.

Edema of the Vesical Wall Secondary to Cystitis

As noted previously, valves vary in their degrees of incompetence. A "borderline" junction may not allow reflux when the urine is sterile, but valvular function may be impaired when cystitis causes associated edema involving the trigone and intravesical ureter. In addition, the abnormally high voiding pressure may lead to reflux, in which case, secondary pyelonephritis may ensue. After cure of the infection, cystography again reveals no reflux. It is believed that a completely normal junction will not decompensate even under these circumstances.

It has been shown that pyelonephritis of pregnancy is associated with VUR. Many patients give a history of urinary tract infections during childhood. The implication is that they "outgrew" reflux at puberty, but if bacteriuria becomes established during pregnancy, their "borderline" valves may become incompetent. This condition may be aggravated by the hormones of pregnancy, which may contribute to a further loss of tone of the ureterotrigonal complex. After delivery, reflux is usually no longer demonstrable (Hutch and Amar, 1972).

Eagle–Barrett (Prune Belly) Syndrome

The Eagle–Barrett syndrome is a relatively rare condition in which there is failure of normal development of the abdominal muscles and the smooth muscle of the ureters and bladder. Bilateral cryptorchidism is the rule. At times, talipes equinovarus and hip dislocation are also noted. Because the smooth muscle of the ureterotrigonal complex is deficient, reflux is to be expected; advanced hydroureteronephrosis is therefore found.

Iatrogenic Causes

Certain operative procedures may lead to either temporary or permanent ureteral regurgitation.

Prostatectomy

With any type of prostatectomy, the continuity of the superficial trigone is interrupted at the vesical neck. If the proximal trigone moves upward, temporary reflux may occur. This mechanism may account for the high fever (and even bacteremia) that is sometimes observed when the catheter is finally removed. Fortunately, in 2–3 weeks, the trigone again becomes anchored and reflux ceases.

Preexisting trigonal hypertrophy (due to prostatic obstruction) helps to compensate for the effect of trigonal interruption; thus, reflux may never

occur.

Wedge Resection of the Posterior Vesical Neck

Wedge resection of the posterior vesical neck, often ill advised when performed in conjunction with plastic revision of the vesical neck for supposed vesical neck stenosis or dysfunction, may also upset trigonal continuity and allow reflux.

Ureteral Meatotomy

Extensive ureteral meatotomy may be followed by reflux. Fortunately, however, limited incision of the roof of the intravesical ureter divides few muscle fibers, since the fibers have left the roof to join muscle fibers on the floor. Wide resection for treatment of vesical cancer is often followed by ureteral reflux.

Resection of Ureterocele

If the ureteral hiatus is widely dilated, this procedure is often followed by reflux.

Contracted Bladder

A bladder that is contracted secondary to interstitial cystitis, tuberculosis, radiotherapy, carcinoma, or schistosomiasis may be associated with ureteral reflux.

Complications

VUR damages the kidney through one or both of two mechanisms: (1) pyelonephritis and (2) hydroureteronephrosis.

Pyelonephritis

VUR is one of the common contributing factors leading to the development of cystitis, particularly in females. When reflux is present, bacteria reach the kidney and the urinary tract cannot empty itself completely, so infection is perpetuated. Pyelonephritis is discussed in more detail in Chapter 14.

Hydroureteronephrosis (See Also Chapter 12)

Dilation of the ureter, renal pelvis, and calyces is usually observed in association with reflux (Figure 13–7), sometimes to an extreme degree (Figure 13–8). In males, because they have a relatively long segment of sterile urethra, such changes are often seen in the absence of infection. Sterile reflux is less damaging than infected reflux.

Figure 13–7.

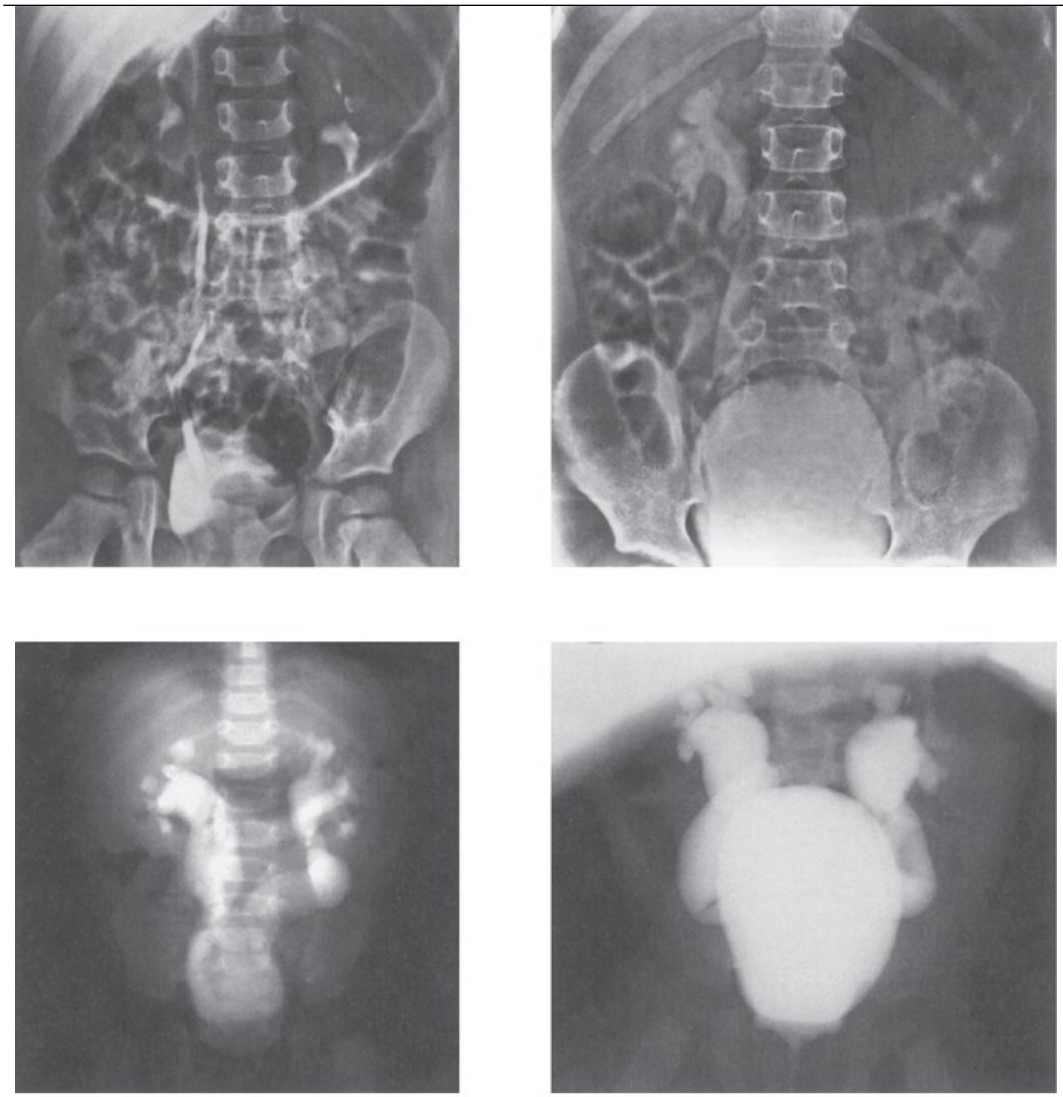

Source: McAninch JW, Lue TF: *Smith & Tanagho's General Urology*, 18th Edition:
www.accessmedicine.com

Excretory urogram with changes that imply right vesicoureteral reflux. ***Upper left:*** Excretory urogram showing normal right urogram and a ureter that is mildly dilated and remains full through its entire length. The ureteral change implies reflux. ***Upper right:*** Cystogram demonstrates the reflux. Note, now, the degree of dilatation of the ureter, pelvis, and calyces. ***Lower left:*** Excretory urogram shows bilateral hydroureteronephrosis with pyelonephritic scarring. These findings imply the presence of reflux. ***Lower right:*** Voiding cystourethrogram. Free reflux bilaterally.

Figure 13–8.

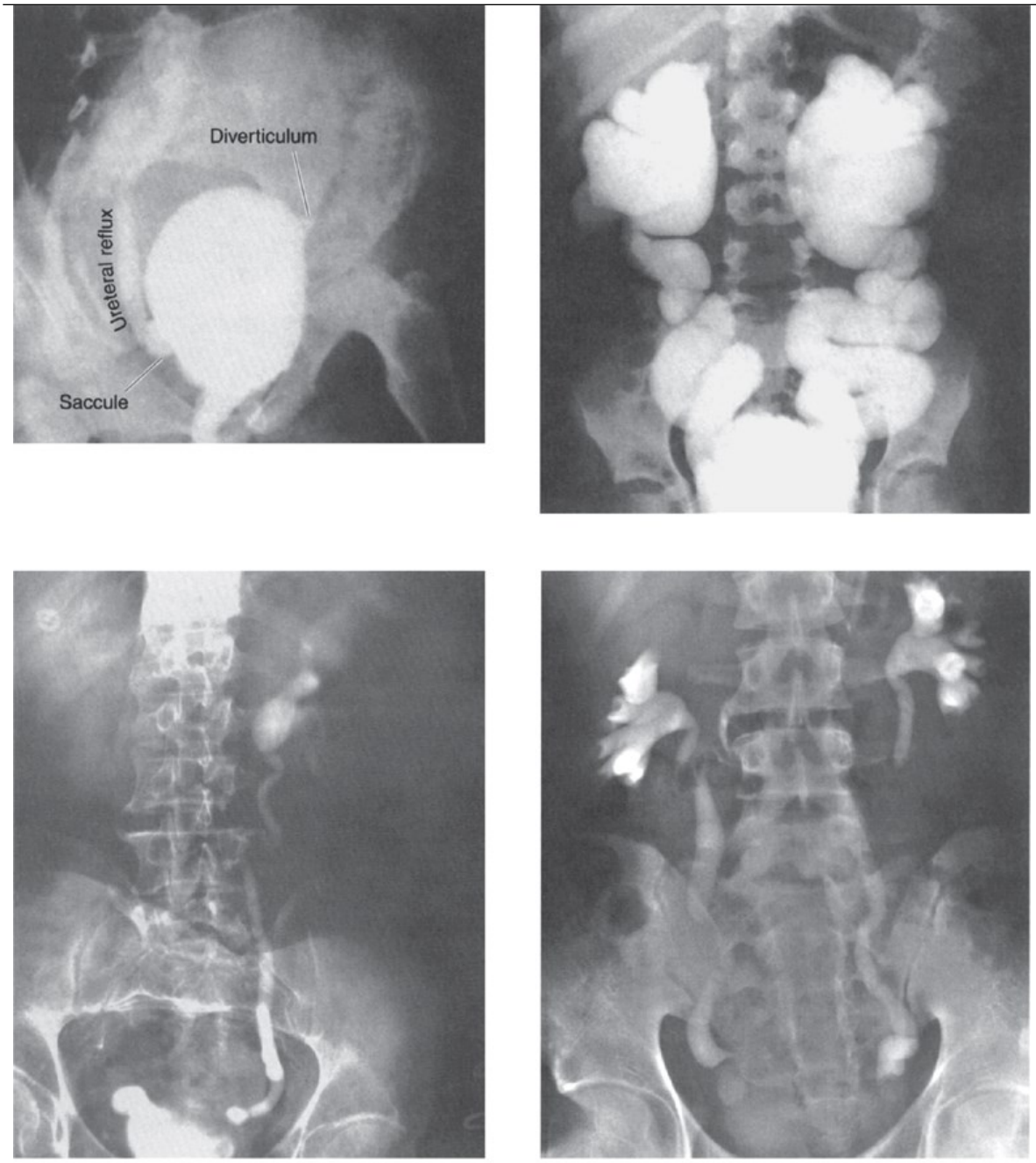

Source: McAninch JW, Lue TF: *Smith & Tanagho's General Urology*, 18th Edition:
www.accessmedicine.com

Cystograms revealing vesicoureteral reflux. ***Upper left:*** Saccule at right ureterovesical junction. ***Upper right:*** Meningomyelocele. Reflux with severe bilateral hydroureteronephrosis; serum creatinine, 0.6 mg/dL; phenolsulfonphthalein excretion, 5% in 1 hour. ***Lower left:*** Postprostatectomy patient with reflux on left and bilateral saccules. ***Lower right:*** Ten-year-old boy with meningomyelocele. Bladder has been emptied. Impairment of drainage at ureterovesical junctions is demonstrated. (Courtesy of Hutch JA, Amar AD: *Vesicoureteral Reflux and Pyelonephritis.* Appleton-Century-Crofts, 1972.)

There are three reasons for the dilatation:

1. **Increased work load:** The ureter is meant to transport the urine secreted by the kidney to the bladder only once. In the presence of reflux, variable amounts of urine go back and forth, and the work load may be doubled, quadrupled, or increased 10-fold or even more. Eventually, the ureter is not able to transport the increased volume of urine, and stasis and dilatation result.

2. **High hydrostatic pressure**: The ureter is protected from the high pressures of the urinary bladder by a competent ureterovesical junction. If there is free reflux, the high intravesical pressure is directly transmitted to the ureteral and pelvic walls, which results in marked stretching and dilation.

3. **Weak ureteral musculature**: In reflux, the ureteral wall is invariably deficient in musculature to some degree. The more severe the reflux, the more apparent the muscular deficiency. Some cases show more massive dilatation than others. The properly muscularized ureter is better able to resist and compensate for overwork and hydrostatic pressure than the muscularly deficient ureter. The latter tends to undergo further dilatation once it is subjected to any increased intraluminal pressure.

Whether sterile reflux is harmful is the subject of controversy. My colleagues and I believe there is conclusive evidence that severe sterile reflux can lead to parenchymal damage. Pyelointerstitial backflow or pyelotubular backflow under the high pressures of reflux (not infrequently seen during cystographic studies) leads to extravasation of urine in the interstitium of the kidney. The presence of urine in any interstitium will result in a marked inflammatory response with cellular infiltration, resulting finally in fibrosis and scarring. On a long-term basis, this can lead to parenchymal changes indistinguishable from pyelonephritic scarring caused by inflammation due to bacterial infection. This damage may be termed **reflux nephropathy**. If severe, it will produce parenchymal damage serious enough to lead to end-stage kidney disease.

Ransley's studies (1976) indicate that intrarenal reflux is more likely to occur in the presence of flat, concave, or compound papillae, because their collecting ducts tend to open with an increase in intrapelvic pressure and reflux. Papillae prone to reflux are more commonly seen in the polar segments of the kidney. Normal papillae might also permit intrarenal reflux if flattened as a result of the changes due to reflux.

Intravesical pressure is transmitted through the incompetent ureteral orifice. This back pressure is quite high at the time of voiding. Furthermore, the ureteropelvic and ureterovesical junctions are less distensible than the rest of the ureter. Either junction may have trouble passing the normal amount of secreted urine plus the refluxed urine; functional obstruction may result. A common cause of ureteropelvic and ureterovesical “obstruction” is VUR. Such changes indicate the need for cystography.

Incidence

VUR occurs in 25–40% (Fanos and Cataldi, 2004) of children with urinary tract infection but in only 8% of adults with bacteriuria. This discrepancy is explained by the fact that girls usually have pyelonephritis, whereas women usually have cystitis only. Bacteriuria does not always imply pyelonephritis.

The fairly competent (borderline) valve refluxes only during an acute attack of cystitis. Since cystography is performed in such cases only after the infection has been eradicated, the incidence of reflux found on cystography is abnormally low. On the other hand, reflux is demonstrable in 85% of patients whose excretory urograms reveal significant changes typical of healed pyelonephritis.

When infection associated with reflux occurs during the first few weeks of life, many patients are septic and uremic. Most are boys with posterior urethral valves. After 1 year of age, the female:male ratio of children with infection and reflux is approximately 3:1–4:1.

Clinical Findings

A history compatible with acute pyelonephritis implies the presence of VUR. This is most commonly seen in females, particularly young girls. Persistence of recurrent “cystitis” may suggest the possibility of reflux. Such patients often have asymptomatic low-grade pyelonephritis.

Symptoms Related to Reflux

Symptomatic Pyelonephritis

The usual symptoms in adults are chills and high fever, renal pain, nausea and vomiting, and symptoms of cystitis. In children, only fever, vague abdominal pains, and sometimes diarrhea are apt to occur.

Asymptomatic Pyelonephritis

The patient may have no symptoms whatsoever. The incidental findings of pyuria and bacteriuria may be the only clues. This fact points up the need

for a screening urinalysis in all children.

Symptoms of Cystitis Only

In cases of symptoms of cystitis only, bacteriuria is resistant to antimicrobial drugs, or infection quickly recurs following treatment. These patients may have reflux with asymptomatic chronic pyelonephritis.

Renal Pain on Voiding

Surprisingly, renal pain on voiding is a rare complaint in patients with VUR.

Uremia

The last stage of bilateral reflux is uremia due to destruction of the renal parenchyma by hydronephrosis or pyelonephritis (or both). The patient often adjusts to renal insufficiency and may appear quite healthy. Many renal transplants are performed in patients whose kidneys have deteriorated secondarily to reflux and accompanying infection. Early diagnosis, based on careful urinalysis, would have led to the proper diagnosis in childhood. Progressive pyelonephritis is, with few exceptions, preventable.

Hypertension

In the later stages of atrophic pyelonephritis, a significant incidence of hypertension is observed.

Symptoms Related to the Underlying Disease

The clinical picture is often dominated by the signs and symptoms of the primary disease.

Urinary Tract Obstruction

Young girls may have hesitancy in initiating the urinary stream and an impaired or intermittent stream secondary to spasm of the periurethral striated muscle (see “Distal Urethral Stenosis” in Chapter 41). In males, the urinary stream may be slow as a result of posterior urethral valves (infants) or prostatic enlargement (men older than 50 years).

Spinal Cord Disease

The patient may have a serious neurogenic disease such as paraplegia, quadriplegia, multiple sclerosis, or meningomyelocele. Symptoms may be limited to those of neurogenic bladder: incontinence of urine, urinary retention or large residual volume, and vesical urgency.

Physical Findings

During an attack of acute pyelonephritis, renal tenderness may be noted. Its absence, however, does not rule out chronic renal infection. Palpation and percussion of the suprapubic area may reveal a distended bladder secondary to obstruction or neurogenic disease. The finding of a hard midline mass deep in the pelvis in a male infant is apt to represent a markedly thickened bladder caused by posterior urethral valves. Examination may reveal a neurologic deficit compatible with a paretic bladder.

Laboratory Findings

The most common complication of reflux, particularly in females, is infection. Bacteriuria without pyuria is not uncommon. In males, the urine may be sterile because of the long, sterile urethra.

The serum creatinine may be elevated in the advanced stage of renal damage, but it may be normal even when the degree of reflux and hydronephrosis is marked (Figure 13–8, upper right).

X-Ray Findings

The plain film may reveal evidence of spina bifida, meningomyelocele, or the absence of the sacrum and thus point to a neurologic deficit. Even in VUR, excretory urograms may be normal, but usually, one or more of the following clues to the presence of reflux is noted (Figure 13–7): (1) a persistently dilated lower ureter, (2) areas of dilatation in the ureter, (3) ureter visualized throughout its entire length, (4) the presence of hydroureteronephrosis with a narrow juxtavesical ureteral segment, or (5) changes of healed pyelonephritis (caliceal clubbing with narrowed infundibula or cortical thinning). A normal intravenous urogram does not rule out reflux.

The presence of ureteral duplication suggests the possibility of reflux into the lower pole of the kidney. In this case, hydronephrosis or changes compatible with pyelonephritic scarring may be seen. Abnormality of the upper segment of a duplicated system can be caused by the presence of an ectopic ureteral orifice with reflux or by obstruction secondary to a ureterocele.

Reflux is diagnosed by demonstration of its existence with one of the following techniques: simple or delayed cystography, voiding cystourethrography, or voiding cinefluo-roscopy. Radionuclide scanning can be used: 1 mCi of ^{99m}Tc is instilled into the bladder along with sterile saline solution, and the gamma camera will reveal ureteral reflux.

Reflux can be demonstrated by a technique using indigotindisulfonate sodium (indigo carmine), a blue dye. The bladder is filled with sterile water containing 5 mL of indigo carmine per 100 mL, after which the patient voids and the bladder is thoroughly flushed out with sterile water. The ureteral orifices are then viewed cystoscopically for blue-tinged efflux. This technique has the advantage that no ionizing radiation is used, and its efficiency is equal to that of voiding cystourethrography. In general, reflux demonstrable only with voiding implies a more competent valve than does reflux that occurs at low pressures. As has been pointed out, failure to demonstrate reflux on one study does not rule out intermittent reflux.

The voiding phase of the cystogram may reveal changes compatible with distal urethral stenosis with secondary spasm of the voluntary periurethral muscles in girls (Figure 39–1) or changes diagnostic of posterior urethral valves in young boys.

Instrumental Examination

Cystoscopy

Most young girls with reflux have smooth-walled or only slightly trabeculated bladders. Chronic cystitis, ureteral duplication, or ureterocele may be evident. An orifice may be ectopic and be found at the bladder neck or even in the urethra. As the bladder is filled, a small diverticulum may form on the roof of the ureteral orifice (Figure 13–6). These findings imply the possibility of reflux. The major contribution of cystoscopy is to allow study of the morphologic characteristics of the ureteral orifice and its position in relation to the vesical neck (Figure 13–9). However, cystoscopy should not be performed as a part of the workup for reflux. Rather, it can be performed prior to surgical correction to help define the anatomic and rule out other bladder and ureteral anomalies.

Figure 13–9.

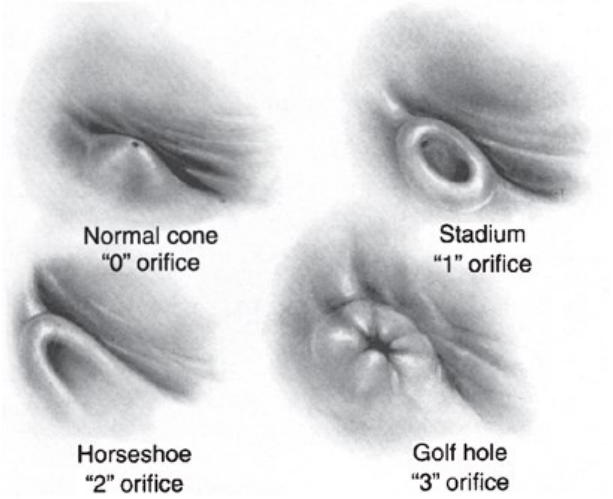

Source: McAninch JW, Lue TF: *Smith & Tanagho's General Urology*, 18th Edition: www.accessmedicine.com

Cystoscopic appearance of the normal ureteral orifice and 3° of incompetence of the ureterovesical junction. (See also Figure 13–4.) (Reproduced, with permission, from Lyon RP et al: The ureteral orifice: Its configuration and competency. J Urol 1969;102:504.)

Morphology

The orifice of a normal ureter has the appearance of a volcanic cone. That of a slightly weaker valve looks like a football stadium; an even weaker one has the appearance of a horseshoe with its open end pointing toward the vesical neck. The completely incompetent junction has a golf-hole orifice that lies over the ureteral hiatus.

Position

By and large, the more defective the appearance of the ureteral orifice, the farther from the vesical neck it lies. The degree of lateralization of the orifice reflects the degree of ureterotrigonal deficiency.

Differential Diagnosis

Functional (nonocclusive) vesicoureteral obstruction may cause changes similar to those suggesting the presence of reflux on excretory urography. Multiple cystograms fail to show reflux. Tanagho et al (1970) showed that this congenital obstruction is due to an abundance of circularly oriented smooth-muscle fibers in the ureteral musculature at this point. Its action is sphincteric.

Significant obstruction distal to the vesical neck leads to hypertrophy of both the detrusor and trigonal muscles. The latter exert an exaggerated pull on the intravesical ureter and thus cause functional obstruction (Tanagho and Meyers, 1965). Hydroureteronephrosis is therefore to be expected; VUR is uncommon.

Other lesions that may cause hydroureteronephrosis without reflux include low ureteral stone, occlusion of the ureter by cervical or prostatic cancer, urinary tract tuberculosis, and schistosomiasis.

Treatment

It is impossible to give a concise and definitive discourse on the treatment of VUR because of the many factors involved and because there is no unanimity of opinion among urologists on this subject. In general, probably more than half of the cases of primary reflux that occur in children can be controlled by nonsurgical means; the rest require some form of operative procedure. Adults with reflux usually require vesicoureteroplasty.

Medical Treatment

Indications

In the majority of the cases, children with primary reflux are initially treated medically, since there is a chance of spontaneous resolution. Positive predictors for reflux resolution include unilateral reflux, the lower grades of reflux, the earlier age of presentation, and male gender (Estrada et al, 2009). A boy with posterior urethral valves may cease to have reflux once these valves are destroyed.

In a woman who occasionally develops acute pyelonephritis following intercourse but whose urine quickly clears on antimicrobial therapy, reflux will probably be controlled if she takes steps to prevent vesical infections. This is particularly true if reflux cannot be demonstrated cystographically when her urine is sterile. The maintenance of sterile urine allows her “borderline” valve to remain competent.

Methods of Treatment

Urinary infection should be definitively treated with antimicrobial drugs, after which chronic suppressive therapy should be continued until the reflux has resolved or surgically corrected. However, recent studies have challenged the effectiveness of prophylactic antibiotics in the treatment of children with VUR (reviewed by Koyle and Caldamone, 2007). A similar urinary tract infection rate of approximately 23% was seen in those receiving and not receiving prophylactic antibiotics. In addition, no difference was observed in the renal damage among VUR patients randomized to receive antibiotic prophylaxis or no antibiotics. Current prospective, randomized trials have been instituted to more definitively evaluate the effectiveness of prophylactic antibiotics in the treatment of patients with primary VUR.

Children with reflux often have voiding dysfunction due to thin-walled bladders and do not perceive the normal urge to void when the bladder is full. Further detrusor tone is lost with overfilling, increasing the likelihood of residual urine. Such children should “void by the clock” every 3–4 hours whether they have the urge or not. Vesical residual urine may then be minimized.

Evaluation of Success of Medical Treatment

Cystograms should be repeated every 12–18 months. Excretory urography or nuclear renal scan should be performed periodically to be sure that renal deterioration does not occur. About half of children with reflux resolve their reflux during observation.

Surgical Treatment

Indications

Reflux caused by the following abnormalities will not disappear spontaneously: (1) ectopic ureteral orifice, (2) ureteral duplication, (3) ureterocele associated with ureteral duplication and reflux into the uninvolved ureter, and (4) low-pressure reflux with significant hydroureteronephrosis.

Absolute indications for surgery include the following conditions: (1) if it is not possible to keep the urine sterile and reflux persists, (2) if acute pyelonephritis recurs despite a strict medical regimen and chronic suppressive antimicrobial therapy, (3) if increased renal damage is demonstrated by serial excretory urograms or nuclear scan, or (4) if noncompliance with medical treatment. Relative indications for surgery include failure to resolve after prolonged observation period (ie, >3 years), parental decision (avoidance of chronic antibiotic usage or radiologic evaluation), or the presence of a diverticulum.

Types of Surgical Treatment

In cases of markedly impaired kidney function and massively dilated ureters, preliminary urinary diversion may be required to improve renal function and to allow dilated ureters to regain tone, after which definitive relief of obstruction (eg, posterior urethral valves) and ureterovesicoplasty can be performed at the optimum time. Some patients with irreversible lesions causing reflux (eg, meningomyelocele) or badly damaged and atonic ureters may require permanent diversion of the urine (ie, ureteroileocutaneous anastomosis).

Temporary Urinary Diversion

If refluxed urine drains freely into the bladder, cystostomy (or an indwelling urethral catheter in girls) may prove helpful. If the ureters are dilated and kinked, a low redundant loop can be brought to the skin. The ureter is opened at this point and urine collected into an ileostomy bag. Later, the loop

and the section of ureter distal to it can be resected and the ureter proximal to the loop reimplanted into the bladder. Nephrostomy may be necessary if there is no ureteral redundancy.

Permanent Urinary Diversion

If it is felt that successful ureterovesicoplasty cannot be accomplished, a Bricker type of diversion is indicated. If renal function is poor and the ureters are widely dilated and atonic, ureterocutaneous diversion may be the procedure of choice.

Other Surgical Procedures

a. If reflux is unilateral, with the affected kidney badly damaged and the other kidney normal, nephrectomy is indicated.

b. If one renal pole of a duplicated system is essentially functionless, heminephrectomy with removal of its entire ureter should be done. If there is moderate hydronephrosis of one renal pole with duplication, an alternative is anastomosis of the dilated ureter or pelvis to the normal ureter or pelvis. The remainder of the dilated refluxing ureter should be removed.

c. In unilateral reflux, anastomosis of the lower end of the refluxing ureter into the side of its normal mate (transureteroureterostomy) has a few proponents.

Definitive Repair of Ureterovesical Junction (Ureterovesicoplasty)

a. **Principles of repair (Tanagho, 1970)**

   1. Resect the lower 2–3 cm of the ureter in which the muscle is underdeveloped.
   2. Free up enough extravesical ureter so that an intravesical segment 2.5 cm long can be formed.
   3. Place the intravesical ureter in a submucosal position.
   4. Suture the wall of the new ureteral orifice to the cut edge of the trigonal muscle.

b. **Types of operation—**The following procedures satisfy the preceding principles and have been successful in a high percentage of cases: suprahiatal repair, increasing the length of intravesical ureter above the level of the ureteral hiatus (Paquin, 1959; Politano and Leadbetter, 1958); infrahiatal repair, the advancement procedures of Hutch (1963) and Glenn and Anderson (1967); combined supra-and infrahiatal repair, which is the most attractive; and transtrigonal repair (Cohen, 1975).

   If the ureters are unduly tortuous, the redundant portions must be resected. If they are widely dilated, the lower ends must be tailored to a more normal size.

c. **Results of ureterovesicoplasty—**About 93% of patients no longer show reflux after ureterovesicoplasty. About 3% develop ureterovesical stenosis that requires reoperation. At least 75% have and maintain sterile urine without antimicrobial drugs 3–6 months after surgery. Many patients in whom bacteriuria persists have cystitis only. This has been demonstrated by the finding that renal urine specimens collected by ureteral catheters are sterile. Febrile attacks cease. Considering that only the most severe and advanced cases are submitted to surgical repair, these are impressive results, and they exceed by far the cure rates reported when only antimicrobial drugs are used (10–15%). This operation is rightly considered one of the most significant accomplishments of modern urology.

Subureteric Transurethral Injection (Sting)

More recently, endoscopic treatment of reflux has become popular treatment for reflux. A biocompatible material such as Deflux (a mixture of dextranomer microspheres and non-animal-stabilized hyaluronic acid) can be injected into the intramural ureter. The bulking agent allows for the coaptation of the ureteral orifice and intramural ureter (Aaronson, 2005) in order to prevent reflux. The success rate for the STING procedure varies from 70% to 90%, depending upon the grade of the reflux treated. While it does not approximate the cure rate from open surgery, technical improvements and risk factors for failure are gradually being identified that are aimed at improving performance (reviewed by Routh et al, 2010). More recent studies have suggested that VUR may recur following successful endoscopic injection, warranting long-term follow-up (Yucel et al, 2007;

Holmdahl et al, 2010).

Prognosis

In patients with reflux who are judged to have fairly competent valves, conservative therapy as outlined previously is highly successful in the cure of the reflux and therefore of infection.

Patients with very incompetent ureterovesical valves subjected to surgical repair also have an excellent prognosis. A few children, however, have such badly damaged urinary tracts when finally submitted to diagnostic procedures that little help other than permanent urinary diversion can be offered.

Bibliography

Aaronson IA: Does deflux alter the paradigm for the management of children with vesicoureteral reflux? Curr Urol Rep 2005;6(2):152–156. [PubMed: 15717975]

Agarwal S: Vesicoureteral reflux and urinary tract infections. Curr Opin Urol 2000;10:587. [PubMed: 11148730]

Ataei N et al: Screening for vesicoureteral reflux and renal scars in siblings of children with known reflux. Pediatr Nephrol 2004;19(10):1127–1131. [PubMed: 15309597]

Atwell JD, Cox PA: Growth of the kidney following unilateral antireflux surgery. Eur Urol 1981;7:257. [PubMed: 7250158]

Bailey RR, Rolleston GL: Vesicoureteric reflux and reflux nephropathy: The Christchurch contribution. N Z Med J 1997;110:266. [PubMed: 9269288]

Bakshandeh K et al: Vesicoureteral reflux and end stage renal disease. J Urol 1976;116:557. [PubMed: 978803]

Belman AB: Vesicoureteral reflux. Pediatr Clin North Am 1997;44:1171. [PubMed: 9326957]

Birmingham Reflux Study Group: Operative versus non-operative treatment of severe vesicoureteric reflux in children: Five years' observation. Br Med J Clin Res 1987;295:237.

Blake NS, O'Connell E: Endoscopic correction of vesicoureteric reflux by subureteric Teflon injection: Follow-up ultrasound and voiding cystography. Br J Radiol 1989;62:443. [PubMed: 2653551]

Bomalaski MD et al: Vesicoureteral reflux and ureteropelvic junction obstruction: Association, treatment options and outcome. J Urol 1997;157:969. [PubMed: 9072627]

Bourne HH et al: Intrarenal reflux and renal damage. J Urol 1976;115:304. [PubMed: 1255892]

Bower WF et al: Dysfunctional elimination symptoms in childhood and adulthood. J Urol 2005;174(4, Pt 2):1623–1627; discussion 1627–1628.

Carvas F et al: The genetics of primary, nonsyndromic vesicoureteral reflux. Curr Opin Urol 2010;20:336–342. [PubMed: 21475075]

Cohen SJ: Ureterocystoneostomie: Eine neue antireflux Technik. [Ureterocystoneostomy: A new technique for reflux prevention.] Aktuelle Urologie 1975;6:1. [PubMed: 1078259]

Darge K: Diagnosis of vesicoureteral reflux with ultrasonography. Pediatr Nephrol 2002;17:52. [PubMed: 11793136]

de Klerk DP et al: Vesicoureteral reflux and ureteropelvic junction obstruction: Late occurrence of ureteropelvic obstruction after successful ureteroneocystostomy. J Urol 1979;121:816.

Devriendt K et al: Vesico-ureteral reflux: A genetic condition? Eur J Pediatr 1998;157:265. [PubMed: 9578958]

Dewan PA: Ureteric reimplantation: A history of the development of surgical techniques. BJU Int 2000;85:1000. [PubMed: 10792195]

Dewan PA, Anderson P: Ureterocystoplasty: The latest developments. BJU Int 2001;88:744. [PubMed: 11890247]

Duckett JW Jr: Ureterovesical junction and acquired vesicoureteral re-flux. J Urol 1982;127:249. [PubMed: 7062374]

Duckett JW, Bellinger MF: A plea for standardized grading of vesicoureteral reflux. Eur Urol 1982;8:74. [PubMed: 7060618]

Estrada CR Jr et al: Nomograms for predicting annual resolution rate of primary vesicoureteral reflux: Results from 2462 children. J Urol 2009;182(4):1535–1541. [PubMed: 19683762]

Fanos V, Cataldi L: Antibiotics or surgery for vesicoureteric reflux in children. Lancet 2004;364(9446):1720–1722. [PubMed: 15530633]

Garin EH et al: Primary vesicoureteral reflux: Review of current concepts. Pediatr Nephrol 1998;12:249. [PubMed: 9630048]

Glenn JF, Anderson EE: Distal tunnel ureteral reimplantation. J Urol 1967;97:623. [PubMed: 6022427]

Greenfield SP, Wan J: The relationship between dysfunctional voiding and congenital vesicoureteral reflux. Curr Opin Urol 2000;10(6):607–610. [PubMed: 11148733]

Hendren WH: Complications of megaureter repair in children. J Urol 1975;113:228.

Holland NH et al: Relation of urinary tract infection and vesicoureteral reflux to scars: Follow-up of thirty-eight patients. J Pediatr 1990;116:S65.

Holmdahl G et al: The Swedish reflux trial in children: II. Vesicoureteral reflux outcome. J Urol 2010;184(1):280–285. [PubMed: 20488469]

Huland H et al: Vesicoureteral reflux in end stage renal disease. J Urol 1979;121:10. [PubMed: 759625]

Hutch JA: Ureteric advancement operation: Anatomy, technique, and early results. J Urol 1963;89:180. [PubMed: 13955912]

Hutch JA: The mesodermal component: Its embryology, anatomy, physiology and role in prevention of vesicoureteral reflux. J Urol 1972;108:406. [PubMed: 5052247]

Hutch JA, Amar AD: *Vesicoureteral Reflux and Pyelonephritis*. Appleton-Century-Crofts, New York, 1972.

Jodal U et al: Medical or surgical management for children with vesico-ureteric reflux? Acta Paediatr Suppl 1999;88:53. [PubMed: 10588272]

Johnston JH: Vesicoureteric reflux with urethral valves. Br J Urol 1979;51:100. [PubMed: 465966]

Kershen RT, Atala A: New advances in injectable therapies for the treatment of incontinence and vesicoureteral reflux. Urol Clin North Am 1999;26:81. [PubMed: 10086052]

Koff SA: Relationship between dysfunctional voiding and reflux. J Urol 1992;148:1703. [PubMed: 1433592]

Koff SA, Murtagh DS: The uninhibited bladder in children: Effect of treatment of recurrence of urinary infection and on vesicoureteral reflux resolution. J Urol 1983;130:1138. [PubMed: 6606053]

Koo HP, Bloom DA: Lower ureteral reconstruction. Urol Clin North Am 1999;26:167. [PubMed: 10086058]

Koyle MA, Caldamone AA: Part 4: Considerations regarding the medical management of VUR: What have we really learned? Curr Med Res Opin

2007;23(Suppl 4):S21–S25.

Lerner GR et al: Reflux nephropathy. Pediatr Clin North Am 1987;34:747. [PubMed: 3295725]

Lyon RP et al: Treatment of vesicoureteral reflux: Point system based on 20 years of experience. Trans Am Assoc Genitourin Surg 1979;71:146. [PubMed: 575683]

Lyon RP et al: The ureteral orifice: Its configuration and competency. J Urol 1969;102:504. [PubMed: 5343494]

Mundy AR et al: Improvement in renal function following ureteric reimplantation for vesicoureteric reflux. Br J Urol 1982;53:542.

O'Donnell B: Management of urinary tract infection and vesicoureteric reflux in children. 2. The case for surgery. Br Med J 1990;300:1393. [PubMed: 23145981]

Paltiel HJ, Lebowitz RL: Neonatal hydronephrosis due to primary vesicoureteral reflux: Trends in diagnosis and treatment. Radiology 1989;170:787. [PubMed: 2644663]

Paquin AJ Jr: Ureterovesical anastomosis: The description and evaluation of a technique. J Urol 1959;82:573. [PubMed: 14430329]

Politano VA, Leadbetter WF: An operative technique for correction of vesicoureteral reflux. J Urol 1958;79:932. [PubMed: 13539988]

Pope JC IV et al: How they begin and how they end: Classic and new theories for the development and deterioration of congenital anomalies of the kidney and urinary tract, CAKUT. J Am Soc Nephrol 1999;10:2018. [PubMed: 10477156]

Ransley PG: The renal papilla and intrarenal reflux. In: Williams PI, Chisholm GD (eds) *Scientific Foundations of Urology*. Year Book Medical Publishers, Chicago, 1976.

Ransley PG: Vesicoureteral reflux: Continuous surgical dilemma. Urology 1978;12:246. [PubMed: 360557]

Roberts JA: Experimental pyelonephritis in the monkey. 4. Vesicoureteral reflux and bacteria. Invest Urol 1976;14:198. [PubMed: 825481]

Rolleston GL et al: Intrarenal reflux and the scarred kidney. Arch Dis Child 1974;49:531. [PubMed: 4852544]

Rose JS et al: Intrarenal reflux and its relationship to renal scarring. J Urol 1975;113;400.

Routh JC et al: Dextranomer/hyaluronic acid for pediatric vesicoureteral reflux: Systematic review. Pediatrics 2010;125(5):1010–1019. [PubMed: 20368325]

Salvatierra O Jr et al: Primary vesicoureteral reflux and end-stage renal disease. JAMA 1973;226:1454. [PubMed: 4800812]

Salvatierra O Jr, Tanagho EA: Reflux as a cause of end stage kidney disease: Report of 32 cases. J Urol 1977;117:441. [PubMed: 850317]

Seruca H: Vesicoureteral reflux and voiding dysfunction: A prospective study. J Urol 1989;142:494. [PubMed: 2746764]

Shimada K et al: Renal growth and progression of reflux nephropathy in children with vesicoureteral reflux. J Urol 1988;140:1097. [PubMed: 3184282]

Sillen U: Bladder dysfunction in children with vesico-ureteric reflux. Acta Paediatr Suppl 1999;88:40. [PubMed: 10588270]

Skoog SJ et al: A nonsurgical approach to the management of primary vesicoureteral reflux. J Urol 1987;138:941. [PubMed: 3656575]

Smellie JM: Vesico-ureteric reflux. Acta Paediatr 1999;88:1182. [PubMed: 10591417]

Stephens FD: Treatment of megaloureters by multiple micturition. Aust N Z J Surg 1957;27:130. [PubMed: 13488872]

Tanagho EA: Surgical revision of the incompetent ureterovesical junction: A critical analysis of techniques and requirements. Br J Urol 1970;42:410. [PubMed: 5471739]

Tanagho EA: Ureteral tailoring. J Urol 1971;106:194. [PubMed: 4938741]

Tanagho EA: The pathogenesis and management of megaureter. In: Johnston JH, Goodwin WE (eds) *Reviews in Paediatric Urology*. Excerpta Medica, North Holland, The Netherlands, 1974.

Tanagho EA et al: Primary vesicoureteral reflux: Experimental studies of its etiology. J Urol 1965;93:165. [PubMed: 14260208]

Tanagho EA et al: The intravesical ureter in primary reflux. J Urol 1969;101:824. [PubMed: 5771250]

Tanagho EA et al: Pathophysiology of functional ureteral obstruction. J Urol 1970;104:73. [PubMed: 5426713]

Tanagho EA, Jonas U: Reduced bladder capacity: Cause of ureterovesical reflux. Urology 1974;4:421. [PubMed: 4418284]

Tanagho EA, Meyers FH: Trigonal hypertrophy: A cause of ureteral obstruction. J Urol 1965;93:678. [PubMed: 14300271]

Tanagho EA, Pugh RCB: The anatomy and function of the ureterovesical junction. Br J Urol 1963;35:151. [PubMed: 13984800]

Van den Abbeele AD et al: Vesicoureteral reflux in asymptomatic siblings of patients with known reflux: Radionuclide cystography. Pediatrics 1987;79:147.

Verber IG et al: 99mTc dimercaptosuccinic acid (DMSA) scan as first investigation of urinary tract infection. Arch Dis Child 1988; 63:1320. [PubMed: 2849382]

Weiss RA: Update on childhood urinary tract infections and reflux. Semin Nephrol 1998;18:264. [PubMed: 9613867]

Weiss RM, Biancani P: Characteristics of normal and refluxing ureterovesical junctions. J Urol 1983;129:858. [PubMed: 6842725]

Whitaker RH: Reflux induced pelvi-ureteric obstruction. Br J Urol 1976;48:555. [PubMed: 1016828]

White RH: Vesicoureteric reflux and renal scarring. Arch Dis Child 1989;64:407. [PubMed: 2650639]

White RH: Management of urinary tract infection and vesicoureteric reflux in children. 1. Operative treatment has no advantage over medical management. Br Med J 1990;300:1391. [PubMed: 2196948]

Williams DI: The natural history of reflux. Urol Int 1971;26:350. [PubMed: 5136747]

Woodard JR, Rushton HG: Reflux uropathy. Pediatr Clin North Am 1987;34:1349. [PubMed: 3309852]

Woodard JR, Zucker I: Current management of the dilated urinary tract in prune belly syndrome. Urol Clin North Am 1990;17:407. [PubMed: 2186543]

Yucel S et al: Durability of a single successful endoscopic polytetrafluoroethylene injection for primary vesicoureteral reflux: 14 year followup results. J Urol 2007;178(1):265–268. [PubMed: 17499781]